

LIGAMENT PROBLEM IN CHOW CHOW - ONE STEP FORWARD, ONE BACK

By Mai Brit Tørngren, med. vet. and Senior Lecturer Jens Arnbjerg, dr. med. vet. Department of Small Animal Science, The Royal Veterinary and Agricultural University (translation Lis Taul)

Spring of 2003, I wrote a thesis under the auspices of Jens Arnbjerg to finish my veterinary education at The Royal Veterinary and Agricultural University. My thesis was titled "The straight hind legs in Chow Chow – and rupture on Ligamentum cruciatum craniale" ("torn anterior cruciate ligament").

The study consisted of a literature study as well as practical research performed in the autumn of 2002 on 54 Danish Chow Chows. I would like to take this opportunity to thank the Danish Chow Chow Club for its great enthusiasm and interest in the project. Copies of the thesis are handed out to the committee of The Danish Chow Chow Club.

The background for this study is the high prevalence of ruptures of anterior cruciate ligament that can be found in Chow Chows, compared to the non-angular deformity in the hind legs typical for the breed.

Therefore, guidelines have been established for the breed standard, in order to prevent degeneration in the knee joint due to straight hind legs. Such a dramatic change should not take place without scientific evidence, because straight hind legs and a shuffling gait are some of the unique Chow Chow characteristics.

RUPTURE OF THE ANTERIOR CRUCIATE LIGAMENT

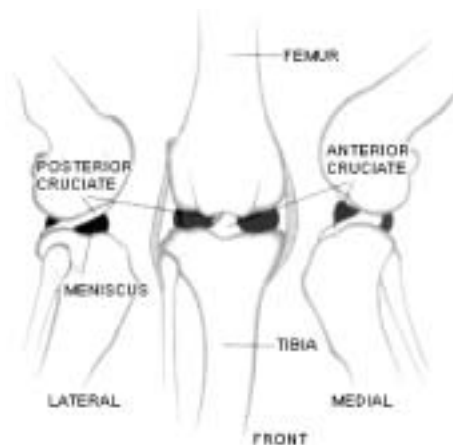
The anterior cruciate ligament has three main functions. Firstly, the ligament prevents front-to-back movement of the shinbone (tibia) to the thighbone (femur). Secondly, it limits exaggerated inward rotation of the shinbone in relation to the thighbone because it twists around the posterior cruciate ligament located on the inner site of the anterior cruciate ligament in the knee joint. Finally, it prevents hyperextension in the knee joint.

Usually, rupture of the anterior cruciate ligament is described in two pathological

scenarios. The acute traumatic type is seen during strenuous exercise resulting in instantaneous lameness. This is particularly noted in big dog breeds. Another scenario is the chronic degenerative type, which especially affects small and intermediate dog breeds. Here, the rupture is caused by prolonged transformation in the actual cruciate ligament in older dogs.

The scenarios may also be combined, resulting in an acute rupture caused by an underlying chronic degeneration of the cruciate ligament.

This acute rupture may only take place in 20% of the dogs, having sustained injury to the anterior ligament.



Degeneration of the cruciate ligament is a process gradually reducing the function of the cruciate ligament over time resulting in a series of microscopic incidents in the interior of the ligament. Hereby, the cruciate ligament is weakened resulting in a partly or complete rupture even under normal strain of the cruciate ligament.

Ruptures of both cruciate ligaments are seen in 8-37% of the dogs, which have sustained injury to the cruciate ligament in one leg. The acute trauma experienced when one anterior cruciate ligament is injured does not in itself increase the predisposition for rupture in both legs, as it does not cause compensatory strain of the non-injured leg. When both legs are injured it is often attributed to a

chronic degenerative process in the anterior cruciate ligament in both legs with a secondary rupture of the cruciate ligaments.

PREDISPOSITION

Unfortunately, there is no unambiguous answer to the substantial cruciate ligament degeneration and tear in some dogs and not in others. However, it is important to note some of the factors that influence the degeneration development. Below are listed some factors, which could increase the risk of sustaining injury to the anterior cruciate ligament. Focus is on the straight construction of the hind leg, which apparently should have relevance to the Chow Chow breed.

Injury of the anterior cruciate ligament is one of the most frequent causes of lameness in the hind legs in dogs. In spite of the fact that this illness affects the dog population in general, an excessive predisposition exists with several different breeds, regardless of the injury being characterized as an acute trauma or a chronic degeneration.

In the case of Chow Chow, more than 20% of all Danish dogs have experienced a rupture in the anterior cruciate ligament. Foreign studies also suggest a high incidence in the particular breed.

In an average dog population, the incidence is 1.6-1.8%. In the same studies, it is evident that the Chow Chow is over-represented with a 4-16% prevalence.

The above-mentioned degeneration of the cruciate ligament is a natural age dependent process. The cruciate ligament strength is reduced in line with the dog's age and the presence of microscopic changes in the intact cruciate ligament. This development is most evident in dogs weighing over 15 kg. These dogs develop substantial degenerative changes, and these changes are noted earlier than in dogs under 15 kg. The degenerative changes, solely caused by the size and the age of the dog, do not explain why some dogs are affected already at the age of 1-2. This may be caused by a combination of



trauma and degeneration or the amount of exercise.

The dog's sex may affect the predisposition of ruptures in the anterior cruciate ligament; apparently, neutered dogs, and especially neutered bitches, are more often affected than intact dogs and bitches. Whether this is caused by secondary phenomena such as abnormal weight gain, changed hormonal condition, or other facts, remains unknown.

A number of other factors are likely to affect the anterior cruciate ligament rupture, but have not been included in the study. Among these are feeding, obesity, amount of exercise, type of exercise, muscle tone, hormones, ligament quality, illnesses in the joint, and immune-mediated illnesses.

STRAIGHT CONSTRUCTION OF KNEE AND HOCK JOINTS

With respect to the Chow Chow, focus is on the straight construction of the knee and hock joints as a possible cause of accelerated degeneration and consequent rupture of the cruciate ligament.

According to literature, it appears that dogs with the straight hind leg construction is a vulnerable group with respect to partial injuries of the anterior cruciate ligament. A hyperextension knee or hock joint may influence the cruciate ligament by applying exaggerated strain during normal movement, where the anterior cruciate ligament is in its end position and tight.

This abnormal stress factor may result in minor traumas on the cruciate ligament, and the ligament is thus vulnerable to ruptures even at limited tension. This observation is based on standard ligament anatomy. Whether the ligament is stressed to the same degree in dogs with congenital hyperextension has not been studied.

The Chow Chow has a straight hind leg construction. Table 1 shows the average angulation of the Chow Chow compared to the angulation in other dogs. The values for Chow Chow originate from the present study.

Average angulation	Chow Chow	Other breeds
Knee joint	150°	125-140°
Hock joint	167°	135°

Table 1. Average angulation of Chow Chow compared to other breeds.

The breed standard for the Chow Chow establishes that the hind legs must be without distinct angulation seen from the side, and the hock must constitute a straight line below the hip socket. This structure gives the unique shuttle gait. The desired knee and hock joints have minimal angulation, and therefore never flex forward. The hind leg movement is short and swinging like a pendulum because of the straight construction of the hindquarters. The hind legs are moving upwards and forward from the hip in a straight, stilted, shuttle line with limited elasticity of the behind. A significant pressure influences the paw, and energy is transferred to the body in an almost straight line because of the minimal angulation.

During motion, a yielding phase appears right after the landing when the leg is weight bearing. This yielding phase stops the pressure induced by the landing and prepares the leg for set off. This protects the knee joint. The yielding seems to be missing from the description of how the Chow Chow moves, indicating a risk for ligament exposure to exaggerated stress.

When the harm has been done, secondary degenerative changes develop in the knee joint irrespective of the treatment chosen. Therefore, focus should be on preventative efforts. The secondary degenerative changes can be detected by radiography. The straight hind leg construction is, as mentioned previously, a predisposition factor in the Chow Chow breed. Hence, examination of dogs with very straight angulation has been performed to determine if straight angulation results in more pronounced degeneration of the joint than is the case for the rest of the breed.

THE EXAMINATION

A number of Danish Chow Chows have been X-rayed with the primary purpose of

confirming or rejecting whether the straight hind leg construction of the Chow Chow is causing degeneration of the joint.

During examination, X-rays are taken from the side, when the dog is in a natural rest position.

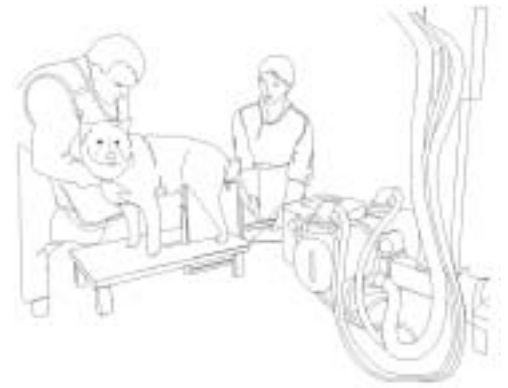

Figure 1. X-ray of the left hind leg with horizontal light path.

Radiology examinations are considered a pilot project. Through X-rays, information is gathered about the natural angulation in the knee and hock joints and the presence of radiological changes. Also the hip joints and the lumbar vertebrae are X-rayed to exclude other explanations of weaknesses in the hindquarters. Additionally, the dogs are examined with respect to lameness. Finally, information about the dog's age, sex, condition, feeding habits, exercise habits, operation status with respect to anterior ligament rupture are available from a distributed questionnaire. Selected information is used in this study.

Defective X-rays with deficient positioning, e.g. rotation, abnormal rest of leg and X-rays of dogs with pronounced HD changes were removed from the study. Totally, X-rays from 11 dogs were eliminated prior to analysis.

The examination revealed that the Chow Chow breed is receptive to rupture of the anterior cruciate ligament. Nine out of 54 (17%) of the examined dogs had been operated due to injury of the cruciate ligament. Of these, four (44%) had undergone operation of both legs. The questionnaire pointed out that all operated dogs had undergone the first operation prior to the age of three, with

an average age of one year and eight months. Of the four dogs with both knees operated, three were less than two years old when the second operation took place. The last dog was seven years old.

In the final statistics, 43 dogs were included, of which four and two had unilateral and bilateral surgery, respectively.

The dogs in the study averaged 49 months (four years) of age. The youngest dog was seven months, whereas the oldest was ten years.

Some of the dogs with apparent, intact cruciate ligament had degenerative changes in the knee joint. A total of 14 (22 joints) dogs had degenerative changes, whereas only six dogs (eight joints) had undergone surgery related to anterior cruciate ligament rupture.

Figure 2 illustrates the age distribution of the dogs in the study and the presence of unilateral or bilateral degenerative changes.

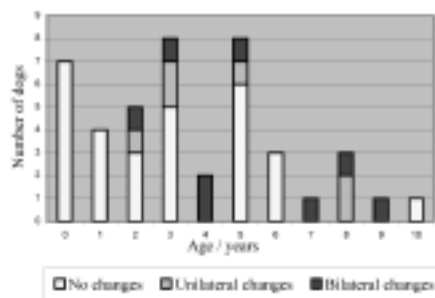


Figure 2. The dogs' age distribution compared to the presence of degenerative changes in one knee (unilateral) or both knees (bilateral).

The main purpose was to determine the normal angulation of the knee joint and the hock joint in Chow Chow and to examine if the dogs with the straightest angulation in the leg also had the highest degeneration of the joint. Table 2 illustrates average angulation measured in knee and hock joints, respectively. Furthermore, minimum and maximum angulations are provided.

Angulation	Avg.	Min.	Max.
Knee joint	150°	120°	170°
Hock joint	167°	133°	188°

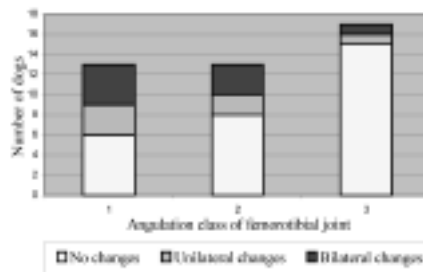
Table 2. Angulation of knee and hock joints.

According to The Danish Kennel Klub (DKK), abnormal construction of the legs (very straight hind legs) causes problems with movement and degeneration of the joint. The fact that Chow Chows have straight hind legs compared to other dog breeds, results in a high incident of cruciate ligament rupture.

Dogs with the straightest angulated legs do not have a higher incident of lameness or degenerative changes in the knee joint. On the contrary, a contradictive tendency is noted in dogs with the most angulated legs, since they also exhibit the highest frequency of lameness and degeneration in the knee joint.

Figure 3 illustrates the distribution of unilateral and bilateral changes in the knee joint compared to the classification of angulation in the joint.

Figure 3. Classification of angulation of the femorotibial joint (1=<145°, 2=145-155°, 3=>155°).



No significant difference occurred in the degeneration of the joint in dogs with the straightest angulation in the knee joint. On the contrary, dogs with degeneration in one or both joints had a less radical angulation (145°) than the dogs without degenerative changes in the knee (155°). Consequently, this does not support the theory that straight hind legs result in degeneration of the joint, and hence, the study does not confirm the stipulation to this effect by the DKK.

The fact that the breed as such has straight legs cannot be controlled by elimination of the dogs in the breed with the widest angulation.

Hence, searching for the background for the cruciate ligament problem in Chow Chow should continue. The occurrence in young dogs could indicate acute incidents of rupture, whereas high incidents of bilateral changes more likely connote a chronic degeneration. Additionally, the number of dogs with degenerative changes, but without a diagnosed illness, will indicate a chronic degeneration. Often, both situations occur simultaneously.

The innate straightness of the hind legs should not result in a constant stress on the anterior cruciate ligament. Adaptation should already have occurred; an adaptation, which could generate a compensatory instability in order not to chronically stress the cruciate ligaments.

Early degeneration of the ligament in Chow Chow might be caused by a cumulative effect of several factors. Chow Chows may have a poor cruciate ligament quality with inadequate dimensions. The weight of the Chow Chow of approx. 20-25 kg puts it in a high risk group of developing natural degeneration in the anterior cruciate ligament at an early age. A reduced degree of tension due to moderate exercise may influence the cruciate ligament strength.

This study shows that it is not feasible to breed your way out of the cruciate ligament problem in Chow Chow by eliminating the dogs with the straightest hind legs. If the problem stems from the quality of the anterior cruciate ligament in one single dog irrespective of its angulation of the legs, dogs with cruciate ligament or degenerative changes could be excluded from breeding. A majority of the dogs experiencing rupture of the cruciate ligament undergo surgery already at ages 1.5 years. Hence, this diagnosis could be used as a selection parameter in Chow Chow breeding.

Further scientific evaluations of the Chow Chow population are required in order to fully elucidate the cruciate ligament problem relative to the breed. ■

